

A Rare Case Of Sino-Nasal Sarcoma With Intracranial Extension: A Case Report

Ahmed Hasan Ashfaq¹, Muhammad Arshad², Nida Riaz³, Fatima Shahid⁴, Salman Aslam⁵, Anique Ahmad Jamil⁶, Shahzaib Maqbool⁷

Abstract

Herein, we are reporting a rare case of sinonasal sarcoma with intracranial extension. Patient presented with complaints of nasal obstruction and epistaxis. The investigations including histopathological analysis were suggesting a highly aggressive sinonasal sarcoma with intracranial extension also involving the internal carotid artery in circumferential manner. Tumor was unresectable due to extent of invasion and patient was referred to radiotherapy department for reduction of tumor size with radiotherapy.

Keywords: Sinonasal sarcoma, intracranial extension, Spindle cells, Fascicular pattern.

¹ Department of Otorhinolaryngology and Head and Neck Surgery.

Correspondence: Ahmed Hasan Ashfaq

1. Introduction

Malignant spindle cell tumors account for 1% of the total head and neck cancers and of all 5-10% are classified as sarcomas in adult population.¹ According to World Health Organization (WHO) classification in 2017, the head and neck sarcomas are divided into eight histological subtypes: undifferentiated pleomorphic sarcoma, fibrosarcoma, angiosarcoma and malignant peripheral nerve sheath tumor (MPNST).¹ Sinonasal sarcoma is one of the unique tumors now presented by WHO and has been added in the classification of head and neck malignancies recently.² Herein we are reporting a rare case of sinonasal sarcoma in 38-years old female presented to department of otolaryngology and head and neck surgery, Benazir Bhutto Hospital, Rawalpindi.

2. Case Presentation

A 38-years old female presented to Outpatient department of otolaryngology and head and neck surgery, Benazir Bhutto Hospital, Rawalpindi with complaints of bilateral complete severe nasal obstruction and intermittent epistaxis. Patient also has history right sided nasal obstruction 13 years back with epistaxis for which intranasal polypectomy was done and symptoms of nasal obstruction and epistaxis were resolved. But now patient again presented with symptoms of B/L nasal obstruction and epistaxis. At presentation patient was vitally stable and laboratory analysis was also normal. On external nasal examination a deformity (expanded vestibule was observed) with increased inter-canthal and inter-pupillary distance but Normal eye movement and reflexes, on anterior rhinoscopy B/L completely

obstructing nasal mass was observed that was bleeding with probing. On palpation, the mass was painful and tender sinuses were present. Nasal patency was absent bilaterally with anosmia bilaterally. No neurological dysfunction was present at the time of presentation. Posterior rhinoscopy was insignificant and there were no significant findings in throat and ear examination. Cervical level II lymph nodes on left side of the neck were palpable.

On X-ray (water's view) of nose and para-nasal sinuses, homogeneous haze in B/L maxillary and frontal sinuses and nasal cavity was observed suggesting polypoidal mass formation as shown in figure 1..

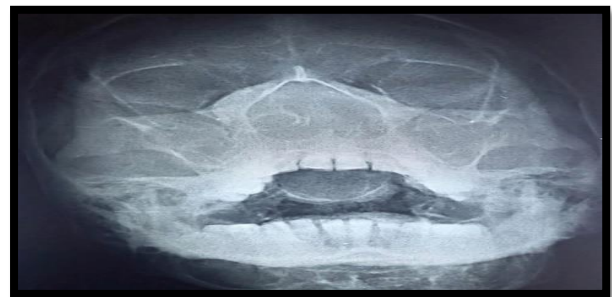


Figure 1: Showing the X-ray PNS (Waters' view) that is delineating the complete obstruction of nasal cavity and maxillary sinuses with Sino-nasal sarcoma

On CECT aggressive looking polypoidal heterogeneously enhancing soft tissue density mass measuring 9x6.3x5.6cm involving nasal cavity and all para-nasal sinuses causing their expansion, obliteration, and bony erosions with intracranial extension was observed as shown in figure 2. MRI scan was suggesting a highly neoplastic mass with bony erosions with intracranial extension and involving right cavernous sinus as well. Tumour was also encircling the internal carotid artery covering 90% of its circumference validating the unresectable mass with intracranial extension. On

incisional biopsy, microscopy showed low grade spindle cell proliferation in fascicular herring bone pattern suggesting sinonasal sarcoma as shown in figure 3. On immunohistochemistry analysis, S-100 was positive

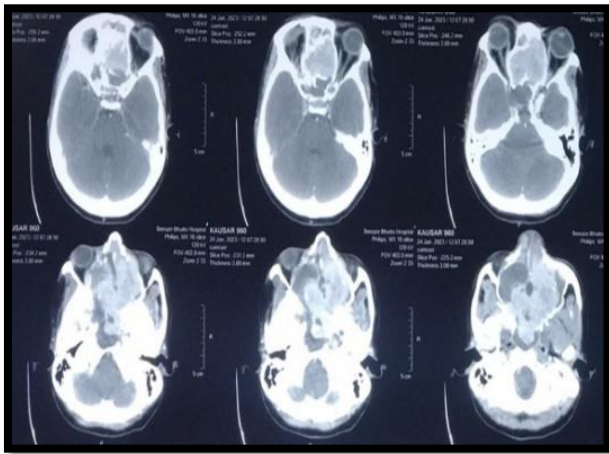


Figure 2: Showing the presence of mass completely obstructing Sino-nasal cavities and with bony erosions and aggressive looking spread

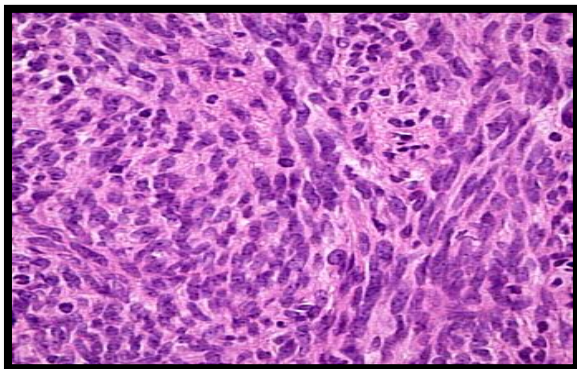


Figure 3: Histological presentation of biopsied sample depicting fascicles of low grade, monotonous spindle cell proliferation in herringbone pattern suggesting sinonasal sarcoma. (H&E).

After all baseline and specific investigation and work up a final diagnosis of sinonasal sarcoma was made and it was labelled as unresectable mass due to intracranial extension and vascular invasions and patient was referred for radiotherapy for reduction in mass volume.

3. Discussion

Sinonasal sarcoma is described as low-grade carcinoma with neural and myogenic differentiation that initially came into literature in 2012 with the efforts of Lewis et al.³ The sarcomas of head and neck are rare and only

accounting for 10% or less of overall head and neck malignancies.⁴ The sarcoma arising from sinonasal cavities is rarely observed location for such kind of low-grade sarcomas. The etiological association of sinonasal sarcoma is not clearly elucidated in the literature, however; the involvement of genetic factors is of paramount significance in the development of sinonasal sarcoma.⁵ Association of sinonasal sarcoma with other diseases like, TP53 mutation, Gardner syndrome, Li-Fraumeni syndrome, tuberous sclerosis, Neurofibromatosis, and irradiation for pre-existing cancer and Epstein-Barr virus infection, have been observed in many studies.⁶

The signs and symptoms of sinonasal sarcoma can vary depending on the location and size of the tumor. Common symptoms include nasal obstruction, congestion, epistaxis (nosebleeds), facial pain or pressure, and sinusitis-like symptoms such as facial swelling, headache, and nasal discharge. Other potential symptoms include vision changes, double vision, eye pain, and proptosis (bulging of the eye).^{7,8} Because these symptoms are non-specific and can also be caused by other conditions such as sinusitis, they can sometimes lead to a delay in diagnosis. However, if a sinonasal sarcoma is suspected, further testing such as imaging studies and biopsy can help to confirm the diagnosis.⁹ Detailed investigations like CT scan, MRI and PET can provide information of paramount significance in terms of size and location of the tumor, as well as whether it has spread to other parts of the body.¹⁰ In addition, newer imaging techniques such as diffusion-weighted MRI and dynamic contrast-enhanced MRI may be useful for evaluating the extent of tumor invasion and vascularity.¹¹ Biopsy is the definitive diagnostic test for sinonasal sarcoma. A tissue sample is taken from the tumor and examined under a microscope to confirm the presence of cancer cells and determine the specific type of sarcoma.¹⁰ Endoscopy and fluorescence-guided endoscopy may be used to visualize the tumor and obtain a tissue sample for biopsy.^{12,13}

The optimal treatment for sinonasal sarcoma depends on various factors such as the type and stage of the tumor, as well as the patient's overall health and preferences. Surgery is the mainstay of treatment for sinonasal sarcoma, and the goal is to remove the entire tumor with negative margins. Depending on the location and extent of the tumor, different surgical approaches such as endoscopic resection, open craniofacial resection, or a combination of both may be used.¹⁴ Adjuvant radiation

therapy may also be given after surgery to reduce the risk of recurrence.¹⁵ Radiation therapy may also be used as the primary treatment for sinonasal sarcoma in some cases, particularly for tumors that are not amenable to surgery or for patients who are not candidates for surgery due to advanced age or comorbidities. Chemotherapy is generally not considered a standard treatment for sinonasal sarcoma due to its limited effectiveness, although it may be used in certain situations such as for unresectable or metastatic tumors.

4. Conclusion

It was a rare case of sinonasal sarcoma of aggressive nature that was completely occupying nasal cavity and para-nasal sinuses with bony erosions. CT scan and MRI was suggesting a highly aggressive mass with intracranial extension (extradural). The mass was also abutting the internal carotid artery with its 90% circumference and was labelled as an unresectable mass and patient was referred for radiotherapy.

CONFLICTS OF INTEREST- None

Financial support: None to report.

Potential competing interests: None to report

References

1. Galy-Bernadot C, Garrel R. Head and neck soft-tissue sarcoma in adults. *European annals of otorhinolaryngology, head and neck diseases*. 2016 Feb 1;133(1):37-42.
2. Thompson LDR, Franchi A. New tumor entities in the 4th edition of the World Health Organization classification of head and neck tumors: Nasal cavity, paranasal sinuses and skull base. *Virchows Arch*. 2018 Mar;472(3):315-330.
3. Lewis JT, Oliveira AM, Nascimento AG, Schembri-Wismayer D, Moore EA, Olsen KD, Garcia JG, Lonzo ML, Lewis JE. Low-grade sinonasal sarcoma with neural and myogenic features: a clinicopathologic analysis of 28 cases. *Am J Surg Pathol*. 2012 Apr;36(4):517-25. Doi: 10.1097/PAS.0b013e3182426886. PMID: 22301502.
4. Stavrakas M, Nixon I, Andi K, Oakley R, Jeannon JP, Lyons A, McGurk M, Urbano TG, Thavaraj S, Simo R. Head and neck sarcomas: clinical and histopathological presentation, treatment modalities, and outcomes. *J Laryngol Otol*. 2016 Sep;130(9):850-9. Doi: 10.1017/S0022215116008604. Epub 2016 Aug 1. PMID: 27476336.
5. Yamaguchi S, Nagasawa H, Suzuki T, Fujii E, Iwaki H, Takagi M, Amagasa T. Sarcomas of the oral and maxillofacial region: a review of 32 cases in 25 years. *Clin Oral Investig*. 2004 Jun;8(2):52-5. Doi: 10.1007/s00784-003-0233-4. PMID: 15281217.
6. Gore MR. Treatment, outcomes, and demographics in sinonasal sarcoma: a systematic review of the literature. *BMC Ear Nose Throat Disord*. 2018 Mar 21;18:4. Doi: 10.1186/s12901-018-0052-5. PMID: 29581706; PMCID: PMC5861608.
7. Mendenhall WM, Mendenhall CM, Werning JW, Riggs CE, Mendenhall NP. Sinonasal carcinoma. *Head Neck*. 2010;32(5):657-666. Doi: 10.1002/hed.21193.
8. Piromchai P, Kasemsiri P, Thanaviratnanich S. Sinonasal sarcoma: a systematic review. *Int Forum Allergy Rhinol*. 2016;6(6):657-663. Doi: 10.1002/alr.21746.
9. Ramakrishnan VR, Suh JD, Chiu AG. Diagnosis and management of sinonasal tumors. *Otolaryngol Clin North Am*. 2011;44(5):1207-1226. Doi: 10.1016/j.otc.2011.06.013.
10. Kuhar HN, Tajudeen BA, Mahajan A, et al. Sinonasal sarcoma: a comprehensive review of imaging, histopathology, and management. *Int Forum Allergy Rhinol*. 2017;7(1):74-79. Doi: 10.1002/alr.21846.
11. Oikonomou A, Mouravas V, Petsas T, et al. The role of MRI in the preoperative staging of sinonasal sarcoma. *Clin Radiol*. 2020;75(5):396-406. Doi: 10.1016/j.crad.2019.12.009.
12. Cho KJ, Cho SH, Kim JH, et al. Endoscopic features of sinonasal sarcoma. *Clin Exp Otorhinolaryngol*. 2015;8(1):80-84. Doi: 10.3342/ceo.2015.8.1.80.
13. Bergamini G, O'Connell D, Vescovi P, et al. Fluorescence-guided endoscopic resection of sinonasal tumors. *Eur Arch Otorhinolaryngol*. 2016;273(2):381-387. Doi: 10.1007/s00405-015-3696-2.
14. Lund VJ, Howard DJ, Harding L, Wei WI. Management options and survival in malignant tumors of the paranasal sinuses. *Laryngoscope*. 1991;101(4 Pt 1):349-353. Doi: 10.1288/00005537-199104000-00001.
15. De Bree R, Haigentz Jr M, Silver CE, et al. Management of the neck in sinonasal cancer. *Head Neck*. 2016;38 Suppl 1:E244-252. Doi: 10.1002/hed.24099.