

## Original Article

# Mammography and Sonomammography as Index Test for Breast Carcinoma keeping Biopsy as a Gold Standard

Sumiya Abid<sup>1</sup>, Sana Shahzadi<sup>2</sup>, Ayesha Imtiaz<sup>3</sup>, Areeba Ikram<sup>4</sup>, Irum Rasheed<sup>5</sup>

## Abstract

**Objective:** To compare breast carcinoma on mammography and sonomammography keeping biopsy as gold standard and to check advantages of biopsy over imaging modalities.

**Study design:** It is an observational study.

**Place and duration of study:** The was carried out in Jahangir SON-X Diagnostic Center, Rawalpindi.

**Material and Methods:** This is an observational study of 150 female patients having breast cancer diagnosed on mammography and sonomammography whose biopsies were also available.

**Results:** On sonography 123 (82%) patients have shown true positive and 09 (6%) have shown true negative results. 18 (12%) patients have shown false positive results. No (0%) patients have shown false negative results. On mammography 123 (82%) have shown true positive results .09 (6%) have shown true negative and 09 (6%) have shown false positive results and 09 (6%) have shown false negative results. In comparison to 100% sensitivity of biopsy, sonomammography is also 100% and mammography is 93.3%. Mammography is 50% specific and sonography is 33.3% specific. Diagnostic accuracy of mammography and sonomammography is 88.2% than 100% accuracy of biopsy.

**Conclusion:** The research illustrates the importance of mammography and sonomammography as its diagnostic accuracy is 88.2% compared to 100% accuracy of biopsy. So, its importance cannot be denied and must be used in correlation to biopsy as in index test for breast carcinoma.

**Keywords:** Breast carcinoma, Mammography, Sonomammography, Fine needle aspiration (FNA), Ultrasound (US)

## 1. Introduction

The mammary gland, or breast, is the most fundamental structure in the pectoral region. Breast cancer is a disease in which growth of breast cells is uncontrolled. Abnormal cells grow more rapidly than healthy cells and it usually starts in ducts. Breast cancer may spread to the skin and lymph nodes affecting the ducts or lobules. It is sometimes referred to as metastasis if it spreads to other body organs. One of the primary causes of death for middle-aged women is breast cancer. Even though breast cancer can be identified in its early stages, misinformation usually results in cases being recognized much later. X-ray mammography was the earlier screening and detection technique for breast cancer. One of its

primary advantages as an early detection technique is its ability to identify small amounts of micro

calcification. It does have certain disadvantages, nevertheless, like the radiation problem, which is detrimental to young women with dense breast tissue, etc<sup>2</sup>. Recent decades have seen an increase in the utilization of MRI and ultrasound as cutting-edge methods for breast cancer screening. There is controversy over how best to treat women who have a high lifetime risk of breast cancer. This is especially true if there is a suspicion of or evidence from, a germline mutation of a breast cancer susceptibility gene (BRCA) causing familial or hereditary breast cancer<sup>13</sup>.

Radiology Department, Holy Family Hospital, Rawalpindi,<sup>1,2,3</sup> Lecturer, Riphah International University, Islamabad.<sup>4,5</sup>

**Correspondence:** Sana Shahzadi, Radiology Department, Holy Family Hospital, Rawalpindi. **Email:** sanshahzadi@gmail.com

Females having strong family history of breast cancer have presence of BRCA1 and BRCA2 genes may have breast cancer. Females with history of early menopause, having no child or first child at late age, obese females and females with unnecessary exposure to radiations are suspected for breast cancer. Females with history of alcoholism and post menopausal hormonal therapy may have suspicion of breast cancer<sup>16</sup>.

The gold standard for an accurate diagnosis of breast cancer is a histopathological assessment. The "triple assessment"—imaging, clinical examination, and needle biopsy—is the standard procedure for diagnosing breast diseases<sup>19</sup>.

Mammography is best for early diagnosis and treatment of breast cancer but limited in females of less than age 35. So it works best for fatty breast of females of age greater than 45. It is generally acknowledged, consequently, that mammography is not a reliable method of screening all breast cancers. By providing false assurance, false negative mammography could delay diagnosis and treatment. Poor mammography technique that excludes the tumor from the area investigated observer error, the radiologic density of the breast, tumor development pattern, and lack of tumor calcification are some of the reasons why mammography fails to identify some breast cancers<sup>5</sup>. Mammography is a widely accepted and cost-effective technique for evaluating clinically suspected breast lesions and for breast cancer screening.

Primarily in dense breasts, sonomammography is a helpful supplementary technique that aids in that describes a palpable abnormality that is not noticed by mammography. According to multiple studies, women with thick breasts who had breast ultrasonography screening and had negative results from clinical exams, mammograms, and other tests reported an additional cancer detection rate of 2.8 to 4.6 cases per 1000 women. Multiple research investigations have demonstrated that breast density is an additional risk factor for the occurrence of breast cancer. Research has indicated that women with dense breasts have lower mammography sensitivity. In addition, further ultrasound screening can detect tumors that would otherwise remain undetected in these women, regardless of their risk level<sup>10</sup>. Sonography is generally not utilized as a screening tool for breast cancer, despite the fact that it is

highly helpful in differentiating breast tumors in cystic lesions. Instead, it is used as a second method to examine breast abnormalities discovered on mammography or during physical examination.

A breast biopsy is a technique to remove small tissue of breast for laboratory testing. It helps in evaluation of suspicious area in breast to determine whether it is breast cancer or not. It is predicted that US guided core needle biopsy of breast tissue and axilla would demonstrate a comparable improvement in sensitivity, as image-guided core needle biopsy has a higher sensitivity than FNA (fine needle aspiration) for assessing breast lesions.

The type of treatment depends upon breast cancer stage. Treatment options include lumpectomy, mastectomy, prophylactic surgery or breast reconstruction. Cancer can also be treated with chemotherapy, radiotherapy, immunotherapy or hormonal therapy<sup>20</sup>.

## 2. Materials & Methods

It was prospective study. 150 female patients are studied with age > 30 years that are presenting with lump. Male patients are not included in the study. Non-probability, convenience sampling technique is used. Data of patients who have undergone mammography, sonomammography and biopsy would be included. The final diagnosis of consultant radiologist and surgeon should be taken final. This may help to understand the effectiveness of mammography sonomammography and biopsy in detecting breast cancer. Mammography and sonomammography was performed according to department protocols. Appropriate statistical data analysis technique by using SPSS 22 will be applied.

## 3. Results

In my research female patients 45(30%) were of age 31-40 and 33(22%) patients with age 41-50, 45(30%) were of age between 51-60, 18(12%) were between 61-70 and 09(6%) were of age 81-90. 54(36%) have right breast cancer whereas 96(64%) have left breast cancer 135(90%) patients have cancer in upper outer quadrant and 15(10%) patients have cancer in lower outer quadrant.

This observational study was done at holy family hospital. Total 150 patients were included in the study. 54(36%) have right breast cancer whereas 96(64%) have

left breast cancer.135(90%) patients have cancer in upper outer quadrant and 15(10%) patients have cancer in lower outer quadrant.

**Sonomammography findings**

**Table I:** Ultrasound Findings

	Frequency	Percent
<b>Valid true positive</b>	123	82
<b>True negative</b>	9	6
<b>False positive</b>	18	12
<b>Total</b>	150	100

123(82%) patients have shown true positive results and 09(6%) patients have shown true negative results. 18(12%) patients have shown false positive results. No (0%) patients have shown false negative results.

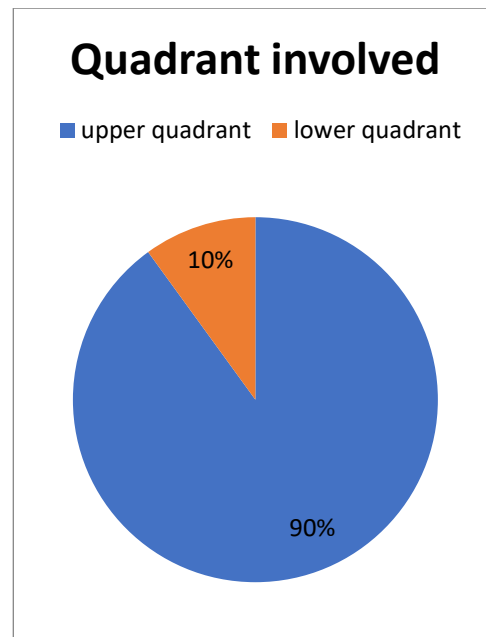
**Mammographic findings:**

**Table II:** Mammography Findings

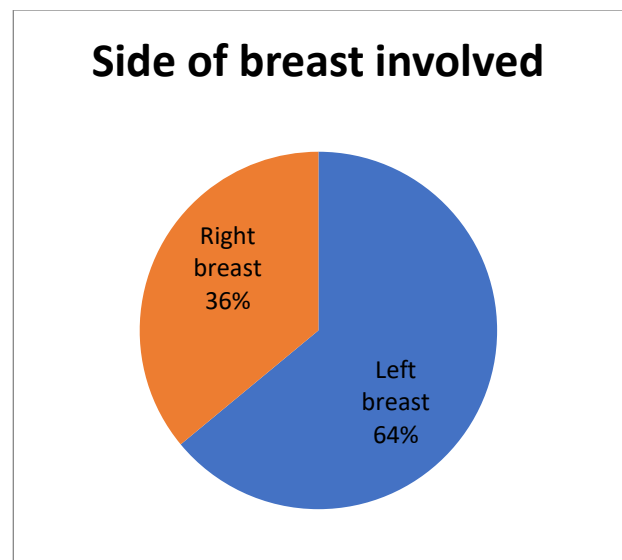
	Frequency	Percent
<b>Valid true positive</b>	123	82
<b>True negative</b>	9	6
<b>False positive</b>	9	6
<b>False negative</b>	9	6
<b>Total</b>	150	100

123(82%) patients have shown true positive results. 09(6%) patients have shown true negative results. 09(6%) patients have shown false positive results. 09(6%) patients have shown false negative results.

**Pie chart I:** Quadrant involved.



**Pie chart II:** Side of breast involved.



The instrument's sensitivity is determined by how well it can identify a problem. Think of a medical test as an example, which is used to determine the ailment. The ability of the test to precisely rule out a condition is known as specificity. Think of a test that is used to identify a medical condition.

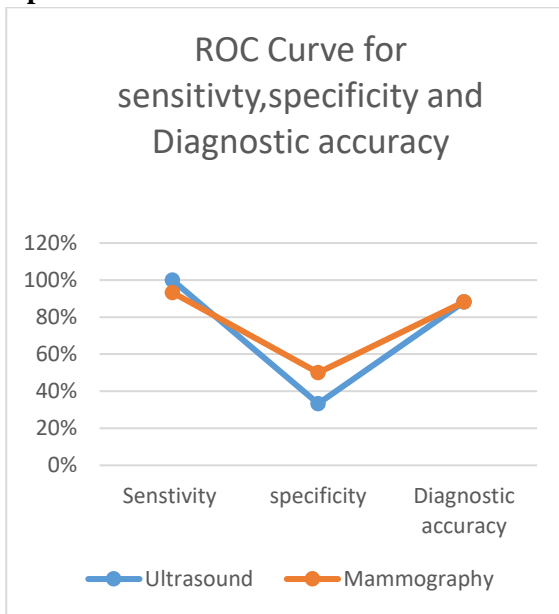
**Table III:** Comparison of sensitivity and specificity and diagnostic accuracy of Sonomammography and Mammography.

**Conclusion:**

Modality	Sensitivity	Specificity	Diagnostic Accuracy	Positive Predictive Value	Negative Predictive Value
Sono-mammography	100%	33.30%	88.20%	87.50%	100%
Mammography	93.30%	50%	88.20%	93.30%	50%

In comparison to 100% sensitivity of biopsy in detecting breast carcinoma sonomammography is also 100% and mammography is 93.3%. Mammography is 50% specific and sonography is 33.3% specific as compared to 100% specificity of biopsy for breast cancer diagnosis. Diagnostic accuracy of mammography and sonography is 88.2% than 100% accuracy of biopsy. So importance of mammography and sonomammography cannot be ignored completely. Biopsy is gold standard but it must be accompanied with mammography and sonomammography.

**Graph 1: ROC Curve**



**4. Discussion**

42(82.4%) patients have shown true positive results and 3(5.9%) patients have shown true negative results. 6(11.8%) patients have shown false positive results. No (0%) patients have shown false negative results. 123(82%) patients have shown true positive results. 09(6%) patients have shown true negative results. 09(6%) patients have shown false positive results. 09(6%) patients have shown false negative results. Sensitivity of mammography in detecting breast cancer is 93.3% that is less than 100% sensitivity of sonomammography. Specificity of mammography in detecting breast cancer is 50% that is more than 33.3% specificity of sonomammography. Diagnostic accuracy of mammography and sonomammography is equal that is 88.2%.

**Limitations:**

The study is based on a relatively small sample size of 150 female patients. A larger sample size would provide more robust and generalizable results, allowing for better conclusions about the accuracy of mammography and sonomammography in breast cancer detection.

The study appears to be cross-sectional in nature, providing a snapshot of the accuracy of mammography and sonomammography at a specific point in time. Longitudinal data, tracking patients over time, would offer insights into the effectiveness of these imaging modalities in detecting breast cancer at different disease stages.

While biopsy is considered the gold standard for diagnosing breast cancer, it may not be without its limitations. Biopsy results can also be subject to interpretation and may have false negatives or false positives, potentially impacting the accuracy comparison with imaging modalities.

**References:**

1. Abdullah R, Abdelmonem L, Nasry N, Ayoub M. Contrast Enhanced Mammography: The added value in the assessment of Suspicious Breast Lesions. QJM: An International Journal of Medicine. 2020 Mar 2;113.
2. Abhisheka B, Biswas SK, Purkayastha B. A comprehensive review on breast cancer detection, classification and segmentation using deep learning. Archives of Computational Methods in Engineering. 2023 Jul 7:1-30.
3. Antabe R, Kansanga M, Sano Y, Kyeremeh E, Galaa Y. Utilization of breast cancer screening in Kenya: what are the

- determinants?. *BMC health services research*. 2020 Dec;20(1):1-9.
4. Edmonds CE, Lamb LR, Mercaldo SF, Sippo DA, Burk KS, Lehman CD. Frequency and cancer yield of BI-RADS category 3 lesions detected at high-risk screening breast MRI. *AJR Am J Roentgenol*. 2020 Feb 1;214(2):240-8.
  5. Edmonds CE, Zuckerman SP, Guerra CE. Racial disparities persist in cancer screening: New USPSTF Colorectal Cancer Screening Guidelines illuminate inadequate breast cancer screening guidelines for black women. *Journal of General Internal Medicine*. 2022 May;37(6):1534-6.
  6. Ezeofor SN, Iloanusi NI, Okere PC. Concerns About Breast Pain: How Useful Is Imaging?. *Health Scope*. 2022 Aug 31;11(3).
  7. Hussein AM, EL-Shinnawy MA, Moftah SG, Nada OM, Hussein RS. Contrast-Enhanced Mammography Versus Dynamic Contrast-Enhanced MRI in the Evaluation of Sonomammographic BI-RADS 3 & 4 Breast Lesions. *QJM: An International Journal of Medicine*. 2023 Jun 1;116(Supplement\_1):hcad069-709.
  8. Hussein AM, EL-Shinnawy MA, Moftah SG, Nada OM, Hussein RS. Contrast-Enhanced Mammography Versus Dynamic Contrast-Enhanced MRI in the Evaluation of Sonomammographic BI-RADS 3 & 4 Breast Lesions. *QJM: An International Journal of Medicine*. 2023 Jun 1;116(Supplement\_1):hcad069-709.
  9. Khan MD, Banerjee S, Tarafdar S, Kundu D. Role of sonomammography and its diagnostic accuracy for evaluating benign and malignant breast lesions. *Int J Res Med Sci*. 2021 May;9(5):1448-53.
  10. Kopans DB, Sharpe Jr RE, Eby PR. Including the method of detection for breast cancer in the Surveillance, Epidemiology, and End Results database is long overdue. *Journal of Medical Screening*. 2023 Aug 25:09691413231197131.
  11. Monticciolo DL, Malak SF, Friedewald SM, Eby PR, Newell MS, Moy L, Destounis S, Leung JW, Hendrick RE, Smetherman D. Breast cancer screening recommendations inclusive of all women at average risk: update from the ACR and Society of Breast Imaging. *Journal of the American College of Radiology*. 2021 Sep 1;18(9):1280-8.
  12. Patro S, Das S, Mohapatra SS. A Comparative Study of Mammography and Sonomammography with FNAC Correlation in Evaluating Palpable Breast Masses. *Annals of the Romanian Society for Cell Biology*. 2021 May 4:14429-39.
  13. Pichert G, Bolliger B, Buser K, Pagani O. Evidence-based management options for women at increased breast/ovarian cancer risk. *Annals of oncology*. 2003 Jan 1;14(1):9-19.
  14. Priyanka B, Ismail M, Shashikumar M, Rajendrakumar N, Nanjaraj CP. A Comparative Study of Mammography and Sonomammography with Histopathology in Evaluating Palpable Breast Masses.
  15. Qaseem A, Lin JS, Mustafa RA, Horwitch CA, Wilt TJ, Clinical Guidelines Committee of the American College of Physicians\*. Screening for breast cancer in average-risk women: a guidance statement from the American College of Physicians. *Annals of internal medicine*. 2019 Apr 16;170(8):547-60.
  16. Rolfes M, Borde J, Möllenhoff K, Kayali M, Ernst C, Gehrig A, Sutter C, Ramser J, Niederacher D, Horváth J, Arnold N. Prevalence of cancer predisposition germline variants in male breast cancer patients: results of the German Consortium for Hereditary Breast and Ovarian Cancer. *Cancers*. 2022 Jul 5;14(13):3292.
  17. Runjjala K, Naidu YT. Combined Mammographic and Sonomammographic Evaluation of Breast Masses. *International Journal of Contemporary Medicine Surgery and Radiology*. 2020;5(1):A162-5.
  18. Sedguli S, Gowda RS, Ranganathan R. Diagnostic Accuracy of MR Mammography in Comparison with Digital Mammography and Sonomammography. *Galician Medical Journal*. 2022 Mar 1;29(1):E202214-.
  19. Sengupta S, Chhabi SR, Singh A. MR Mammography and Sono-mammography in Characterization of Breast Lesions in a Tertiary Care Centre of Eastern India. *Annals of International Medical and Dental Research*.;7(2):22.
  20. Shi J, Liu J, Tian G, Li D, Liang D, Wang J, He Y. Association of radiotherapy for stage I–III breast cancer survivors and second primary malignant cancers: a population-based study. *European Journal of Cancer Prevention*. 2023:10-97.
  21. Tang Y, Tian W, Xie J, Zou Y, Wang Z, Li N, Zeng Y, Wu L, Zhang Y, Wu S, Xie X. Prognosis and dissection of immunosuppressive microenvironment in breast cancer based on fatty acid metabolism-related signature. *Frontiers in Immunology*. 2022 Mar 31;13:843515.
  22. van den Brandt PA, Ziegler RG, Wang M, Hou T, Li R, Adami HO, Agnoli C, Bernstein L, Buring JE, Chen Y, Connor AE. Body size and weight change over adulthood and risk of breast cancer by menopausal and hormone receptor status: a pooled analysis of 20 prospective cohort studies. *European Journal of Epidemiology*. 2021 Jan;36:37-55.
  23. Yamakanamardi S, Hiremath BV. Accuracy of mammography and sonomammography and its correlation with histopathology in the detection of breast cancer. *International Surgery Journal*. 2021 Jan 29;8(2):624-30.
  24. Zielonke N, Gini A, Jansen EE, Anttila A, Segnan N, Ponti A, Veerus P, de Koning HJ, van Ravesteijn NT, Heijnsdijk EA, Heinävaara S. Evidence for reducing cancer-specific mortality due to screening for breast cancer in Europe: A systematic review. *European journal of cancer*. 2020 Mar 1;127:191-206.