

Infarction of Ventral Pons Presenting as Millard-Gubler Syndrome; A Case Report

Haseeb Ahmad¹, Mujtaba Haider Bukhari¹, Murtaza Asghar²

¹ House Officers, Holy Family Hospital, Rawalpindi Medical University

² Senior Registrar, Medical Unit 2, Benazir Bhutto Hospital

Introduction

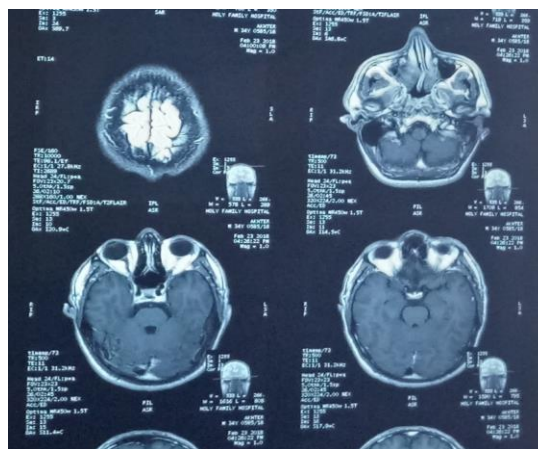
Ventral Pontine Syndrome also called Millard-Gubler Syndrome is defined as a unilateral lesion of the ventral pons at the level of the facial nerve nucleus that presents as unilateral facial nerve and abducens nerve palsy with contralateral hemiplegia.¹ It has been reported that it is caused by infarction, tumor or tuberculosis.^{2,4} This case report describes a patient with ischemic infarction of the left pons presenting as Millard-Gubler syndrome. The diagnosis was confirmed by magnetic resonance imaging (MRI). As the condition is not well-known and it may be misdiagnosed especially in patients with current and/or family histories of other neurological diseases such as multiple sclerosis, it becomes imperative that this case must be reported.

Case Report

A 35 year old male patient came to the emergency room with weakness of right side of the body and slurring of speech since the last 12 hours which was associated with a fall. The patient also noticed diplopia, tinnitus and ataxia by the time he reached the hospital. The patient is a hypertensive for last 7 years with poor control and compliance. The patient was a smoker with 15 pack years and also a cannabis addict. The patient has past history of infertility and urinary retention. There is positive family history of multiple sclerosis. On examination the patient was well oriented. His blood pressure was recorded to be 190/100 mmHg. Flaccid paralysis of right limbs was observed with power of 3/5, brisk tendon reflexes and up going planters were observed. While examining the cranial nerves left sided VII nerve palsy was observed, as an upper motor neuron lesion involving lower half of the face, and left sided VI nerve palsy. Loss of pain, touch, temperature, graphesthesia and proprioception on right side of the body was recorded. Other

findings included horizontal nystagmus, past pointing, ataxic gait and slurred speech. All other systems were found to be normal on examination.

Investigations that were ordered included firstly a CT scan brain, which did not show any hyper-dense area indicative of hemorrhage, and the blood complete picture, urine routine examination, liver function tests and renal function tests that were normal. The ECG and echocardiography were also unremarkable. Another CT scan 24 hours later did not show any signs of stroke.



Figures 1 and 2: MRI showing altered MR signal intensity area in antero lateral part of left half of pons- suggestive of ischemic infarct in ventral pons (Ventral Pontine Syndrome).

The differential diagnoses included multiple sclerosis, as there was positive family history, and stroke involving vertebrobasilar circulation. MRI was awaited and the patient was managed empirically with aspirin, rosuvastatin, omeprazole, lisinopril, methylprednisolone and mecobalamin. The patient was also advised physiotherapy that included strength training and balance and gait exercises. MRI scan indicated ischemic infarct in ventral pons. This

based on the clinical picture suggested ventral pontine syndrome i.e. Millard Gubler syndrome. After 10 days of management the patient's condition improved. The power was improved to 4/5, dysarthria and nystagmus improved, patient regained the sensations of touch, pain, temperature and proprioception with few patchy areas of sensory loss.

Discussion

Millard-Gubler syndrome was described initially by Millard and Gubler as a postmortem diagnosis in the 19th century.⁵ The lesions responsible for the syndrome are located in the basal portion of the caudal part of the pons, which also involves the corticospinal tracts and abducens and facial nerves.⁷⁻⁸ Basilar artery branch occlusion has been implicated as a cause of ventral pontine infarction.^{6,9}

In our case contralateral hemiparesis, ipsilateral cranial nerve VI and VII palsy, ataxia, nystagmus were present in a patient with past history of hypertension and family history of multiple sclerosis. Literature shows that in ischemic pontine syndromes, hemiparesis and cranial nerve palsies with or without other signs mentioned above are present in typical Millard-Gubler syndrome.¹⁰ Literature also shows vertigo, dizziness, transient loss of consciousness and acute pseudo-bulbar palsy and quadriplegia may also be atypical features of pontine infarction, rarely alternating deficits are seen that never correspond to any pontine syndrome.^{10, 11} The MRI findings of Ventral Pontine Syndrome include presence of infarct in the left side of the ventral pons.¹² Small vessel disease is a cause of pontine ischemia and a prior study reveals that 77% patients with pontine stroke had basilar artery atherosclerosis detected on high-resolution MRI.¹³ In this syndrome the cranial nerve palsy is ipsilateral while contralateral upper motor neuron lesion exists in the upper and lower limbs owing to the level of lesion above the decussation of the pyramidal and spinothalamic tracts.

Conclusion

A vertebrobasilar occlusion may result in infarction of the brainstem at the level of facial nucleus and may present as Millard-Gubler syndrome. The clinicians should be aware of various syndromes associated with posterior circulation stroke.

References

1. Matlis A, Kleinman Y, Korn-Lubetzki I. Millard-Gubler syndrome. *AJNR*. 1994 Jan; 15(1):179-81.
2. Sharif M, More V, Purandare S. Brainstem tuberculoma—presenting as millard Gubler syndrome. *Indian J Pediatr*. 2010 Jun; 77(6):707.
3. Loeb C, Meyer JS. Pontine syndromes. *Handb Clin Neurol*. 1969: 238-27
4. Yasuda Y, Matsuda I, Sakagami T, Kobayashi H, Kameyama M. Pontine infarction with pure Millard-Gubler syndrome: precise localization with magnetic resonance imaging. *Eur neurol*. 1993; 33(4):333-4.
5. Gubler A. Memoires sur les paralysies alternes en general et particulier ements sur l' hemiplegie alterne avec lesion de la protuberance annulaire. *Gaz Heb* 1858; 5: 721-723.
6. Hashizume Y, Kishimoto H, Iijima S. Occlusion of the basilar artery: A clinical and pathological study of thirteen autopsied cases. *Pathol Int*. 1984 Jan; 34(1): 29-40.
7. Yasuda Y, Matsuda I, Sakagami T, Kobayashi H, Kameyama M. Pontine infarction with pure Millard-Gubler syndrome: precise localization with magnetic resonance imaging. *Eur Neurol*. 1993; Vol. 33: 333-4.
8. Wall M, Wary SH. The one-and-a-half syndrome, a unilateral disorder of the pontine tegmentum: A study of 20 cases and review of the literature. *Neurology* 1983; Vol. 33: 971-80.
9. Fisher CM, Caplan LR. Basilar artery branch occlusion a cause of pontine infarction. *Neurology*. 1971 Sep; 21(9): 900.
10. Bassetti C, Bogousslavsky J, Barth A, Regli F. Isolated infarcts of the pons. *Neurology*. 1996 Jan; 46(1): 165-75.
11. Kumral E, Bayülkem G, Evyapan D. Clinical spectrum of pontine infarction. *Neurology*. 2002 Dec; 249(12): 1659-70.
12. Onbas O, Kantarci M, Alper F, Karaca L, Okur A. Millard-Gubler syndrome: MR findings. *Neuroradiology*. 2005 Jan; 47(1): 35-7.
13. Klein IF, Lavallée PC, Mazighi M, Schouman-Claeys E, Labreuche J, Amarencu P. Basilar artery atherosclerotic plaques in paramedian and lacunar pontine infarctions: a high-resolution MRI study. *Stroke*. 2010 Jul; 41(7): 1405-9.

Authors Contributions

Haseeb Ahmed: Principal investigator, data acquisition, data analysis and interpretation, **Mujtaba Ahmad Bukhari:** Data Acquisition, analysis and interpretation of data, **Murtaza Asghar:** Acquisition of data

How to Cite this Article: Jalbani, A., Ali Abro, H., Lal, C., Ahmed S., Wahab Shaikh, A., Lal, V. (2019) Infarction of Ventral Pons Presenting as Millard-Gubler Syndrome; A Case Report. *Journal of Rawalpindi Medical College*, 23(S-2), 128-129